

N. Halkic, S. A. Zeini, J. Bouchardey,
M. Boumghar

Service de chirurgie,
CHUV,
Lausanne

Posterior mediastinal neurofibrosarcoma in a patient with von Recklinghausen's disease

The patient is a 40-year-old woman. At age 30, suspicion of neurologic deficit affecting the third cranial nerve. At age 32, excision of a mandibular neurofibroma. At age 41, appearance of continuous right thoracic pain, causing insomnia.

Chest X-ray and CT-scan demonstrate a right paravertebral mass invading T7–T8 nerve roots and the posterior part of the 7th and 8th rib (arrow in fig. 1 and 2). In November 1994, excision of the mass by right thoracotomy (fig. 3).

Histology: neurofibrosarcoma grade III. No adjuvant treatment. Survival of 27 months without signs of recurrence. In 1996, reappearance of right thoracic pain. Repeated thoracotomy and subtotal excision of a recurrent neurofibrosarcoma. Well for 5 months. In October 1996, left lower thoracic pain. A CT-scan and

X-rays demonstrate a left paravertebral thoracoabdominal mass. A course of radiotherapy was tried with no obvious results.

In January 1997, appearance of multiple pleuropulmonary metastases, with worsening of pain, development of an important dyspnoea. Chemotherapy treatment with 18 sessions of epiadriamycin 60 mg i.v. associated with 50 mg amphotericin B i.v. Spectacular disappearance of the symptoms and a very satisfactory partial remission. The patient started working part-time. In May 1998, further deterioration with an increase in the size of the pulmonary masses. The patient died in June 1998.

Post mortem: neurofibrosarcoma with pulmonary and pericardial metastases and double gastric and jejunal neurofibromas.

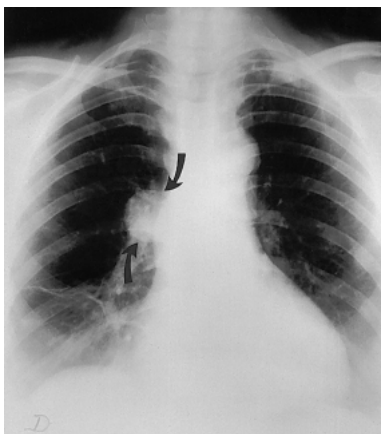


Figure 1

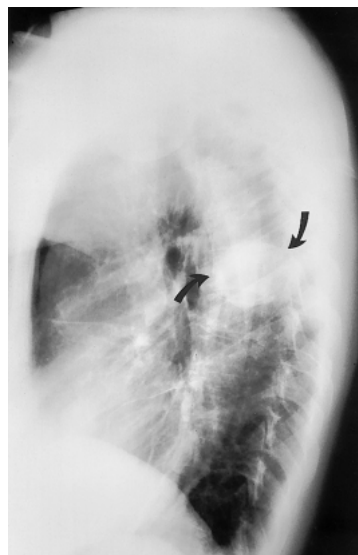

Figure 2

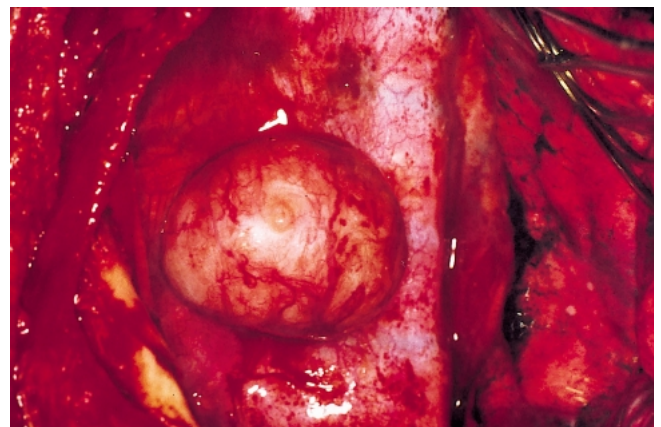


Figure 3

Unter der Rubrik «Coup d'œil» publiziert die Schweizerische Medizinische Wochenschrift Augenfälle aus dem gesamten Bereich der Medizin. Bilder, Graphiken und Darstellungen von allgemeinem Interesse können unter Angabe von Titel, Autor und kurzem Begleittext beim Verlag eingereicht werden.

Correspondence:
Dr. Nermin Halkic,
Service de chirurgie,
CHUV,
CH-1011 Lausanne
e-mail: Nermin.Halkic@chuv.hospvd.ch